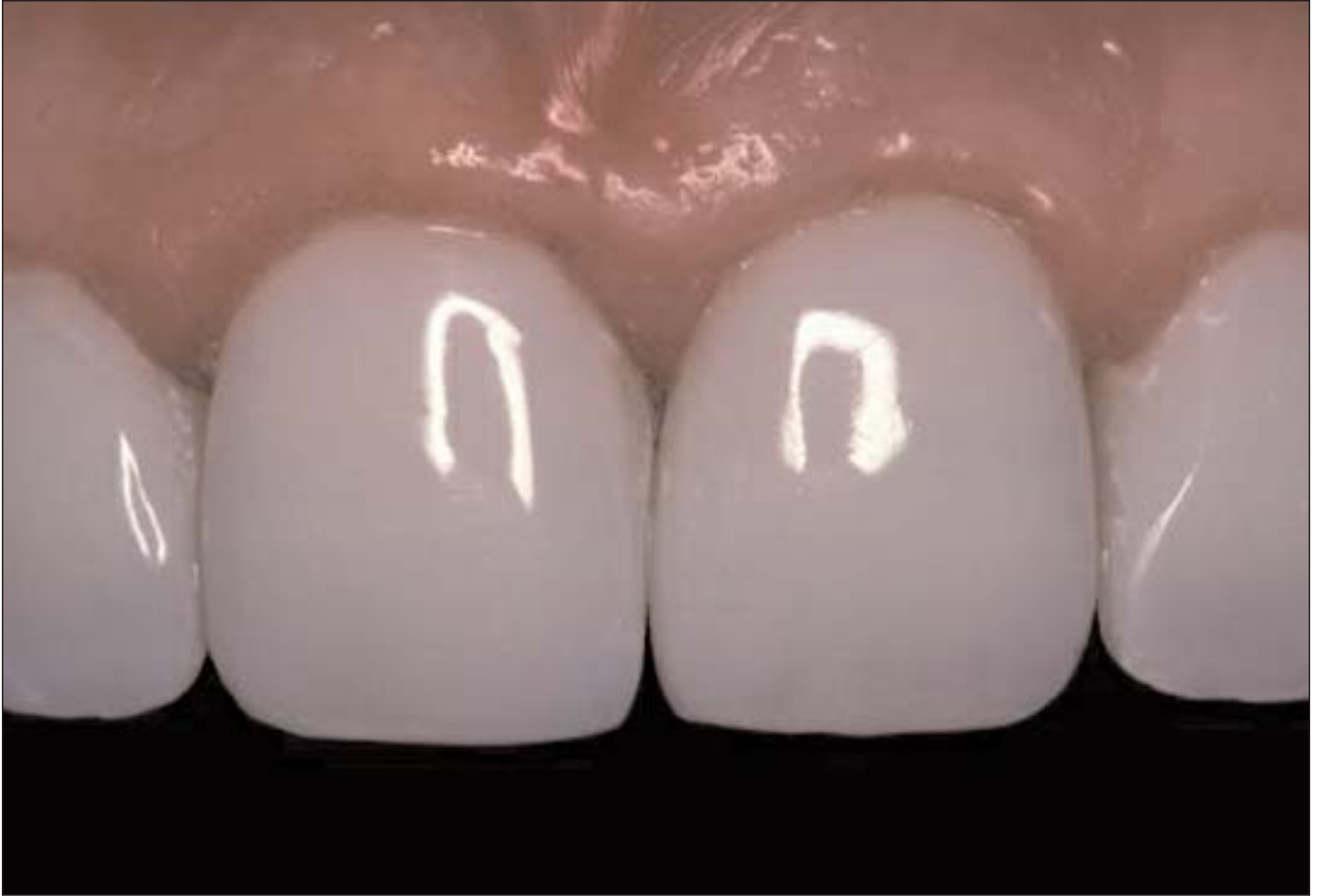

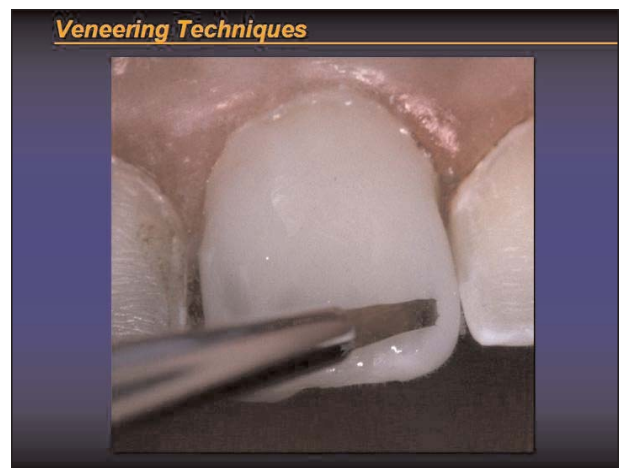
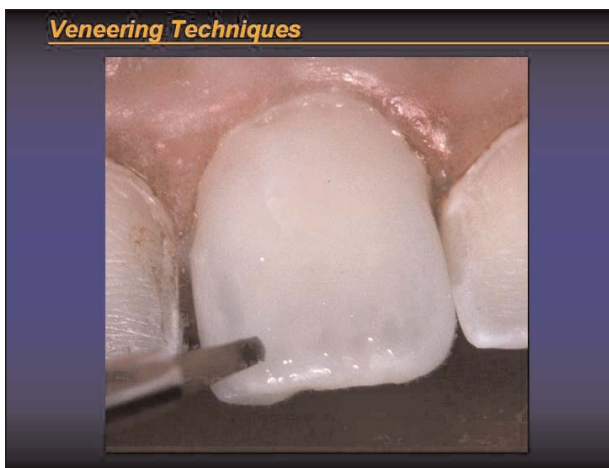

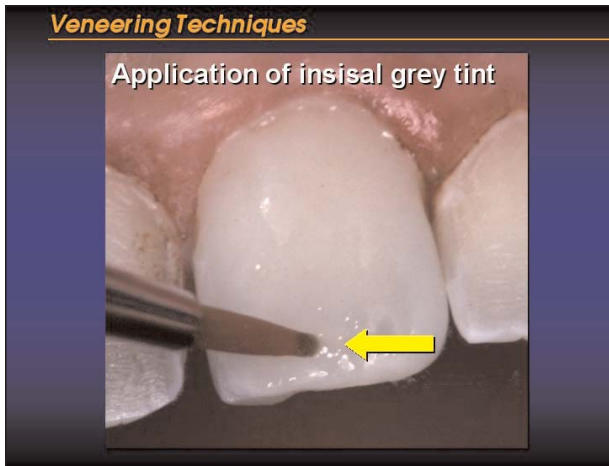
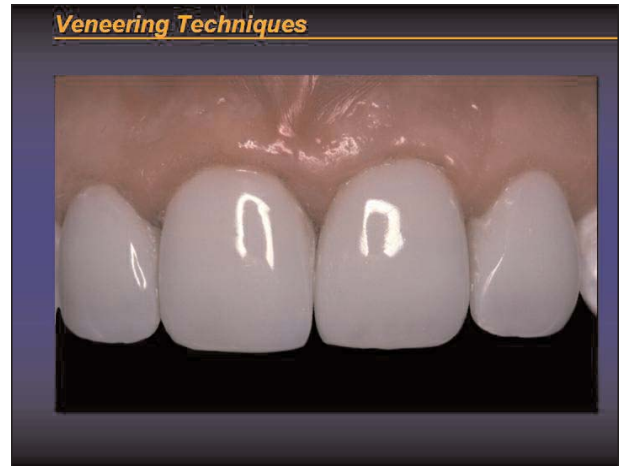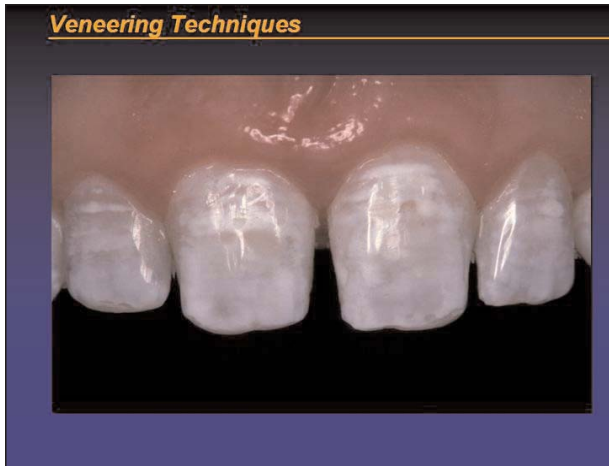Veneering with the Use of Tints

Copyright 2003 by K. William Mopper, DDS, MS

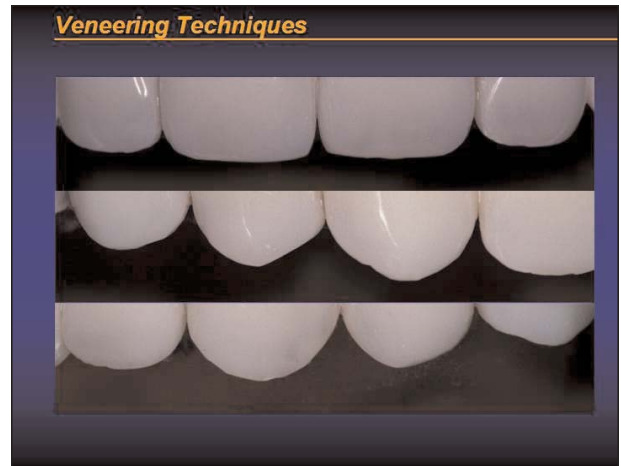
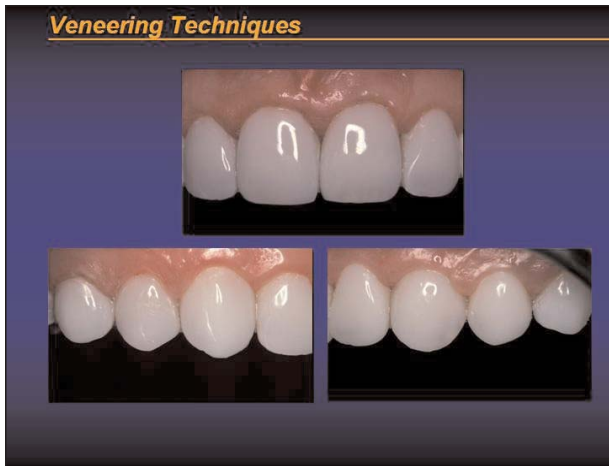
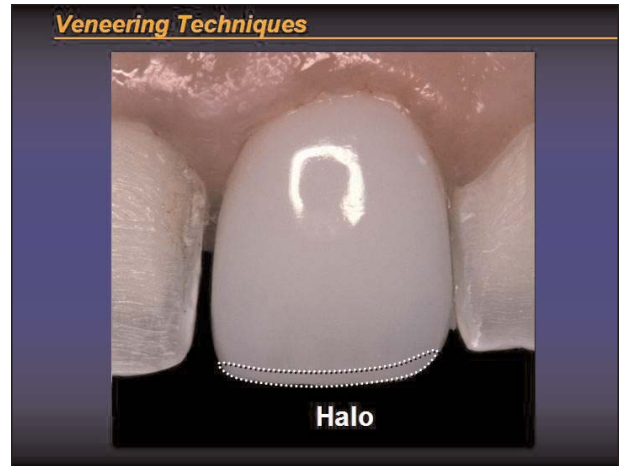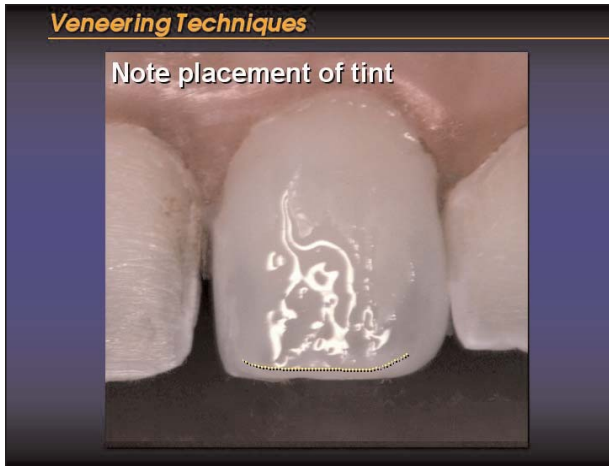
Veneering Techniques

Dr. K. William Mopper



Veneering Techniques

Dr. K. William Mopper



Note the realistic incisal edge development with the use of FlexiDiscs.