

My Turn to Give Back

A Great Smile is an Eye Opener

Buddy Mopper, DDS, MS, FAACD

Introduction

Over the years I have seen what great work the AACD's Charitable Foundation has done for survivors of domestic violence. Their Give Back a Smile™ (GBAS) program encourages AACD members nationwide to volunteer their time and "give back a smile" to survivors of domestic violence with missing or damaged teeth. The impact a smile can have on a person's appearance, confidence, and happiness is profound. Working with this patient reinforced how important a smile is to a person's overall appearance and well-being.

Patient History and Findings

"Diane" presented in early 2010 with a missing maxillary right central incisor, fractured left central incisor, fractured right lateral incisor, and a semi-closed eyelid where her eye had been replaced (Figs 1-3).

Diane was violently attacked by her ex-boyfriend in 2000. The blows to her face were so vicious she lost her upper right central, fractured her right lateral and left central incisor, and suffered such severe damage to her eye it had to be removed.

After meeting Diane and hearing her story of domestic abuse, I was anxious to start treatment as soon as possible.

The impact a smile can have on a person's appearance, confidence, and happiness is profound.

Treatment Planning

When Diane came to my office she was a very sad woman, and understandably so. At the time of the consult I was able to show her, through the use of a direct composite mock-up (Renamel Nano, Cosmedent; Chicago, IL), what she would look like when she was finished. By the end of the mock-up she was so happy with her new smile she started to cry.



The treatment plan was as follows:

1. Repair both fractured incisors.
2. Add enough material to both incisors to allow for proper contouring, spacing, and complete symmetry of both central incisors.
3. Construct a resin retained bridge.
 - a. Trough lingual surfaces of left central incisor and right lateral incisor to allow for the placement of dental fiber reinforcement (Ribbond; Seattle, WA) internally, which would help support the construction of the missing right central incisor.
 - b. Cover exposed Ribbond and properly contour the lingual surfaces of both incisors with the use of nano-fill composite.
 - c. Create a freehand matched right central incisor with proper bonding techniques.

In my opinion, this type of bridge is conservative and more predictable for longevity for the following reasons:

- Lower modulus of elasticity, which allows for the flex of natural dentition and therefore actually becomes less likely to break.
- When fabricating a restoration of this type, you will not see wear on the lower incisors.
- I have found composite resin to give a more predictable esthetic outcome than does porcelain. If the bridge should fracture at the connector site or any other place, it is far easier to repair.
- In my experience, this type of bridge has direct apposition of the composite to the tooth structure, therefore delamination is almost impossible.

Treatment

Both incisal edges were freshened with the use of a coarse FlexiDisc (Cosmedent). A long bevel was placed on the labial of the central and lateral and the lingual surface of each tooth was reduced five-tenths of a millimeter following the end of the long bevel. A chamfer was placed in the same vicinity on the lingual corresponding to the end of the long bevel on the labial. After etching (always etch beyond the long bevel), Cosmedent Complete bonding agent was placed and light-cured. To build up incisal edges and to give strength and opacity, Renamel Nano composite was sculpted to the leading edge of each long bevel and blended just slightly to the middle third of the bevel, which left room for the Renamel Microfill. Nano was also blended onto the lingual surface and sculpted to the lingual chamfered margin, creating a smooth intact lingual surface. Microfill was used for the final layer on the labial surface. It was sculpted past the long bevel and blended into the tooth surface and polymerized. The restorations were contoured, finished, and polished using the ET bur system (Brasseler USA; Savannah, GA) followed by FlexiDiscs, FlexiCups, FlexiPoints, FlexiStrips, Enamelize polishing paste, and felt FlexiBuffs (Cosmedent). This technique was completed prior to the Ribbond placement.¹⁻³

Immediately following treatment, I informed the patient that the restoration might be slightly too light in the gingival third. At her next appointment, that assumption was confirmed (Fig 4).

At the next appointment, I reduced the microfill layer slightly all the way to the middle third of the tooth.



Figure 1: Pre-treatment, full-face image of patient. Notice semi-closed right eye.

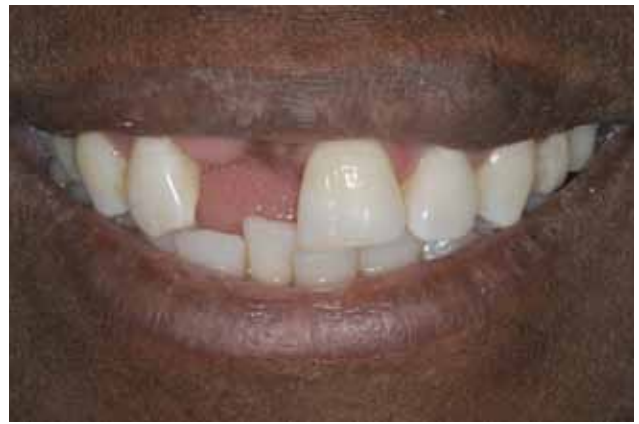

Figure 2: Pre-treatment, natural smile view showing damage from abuse.

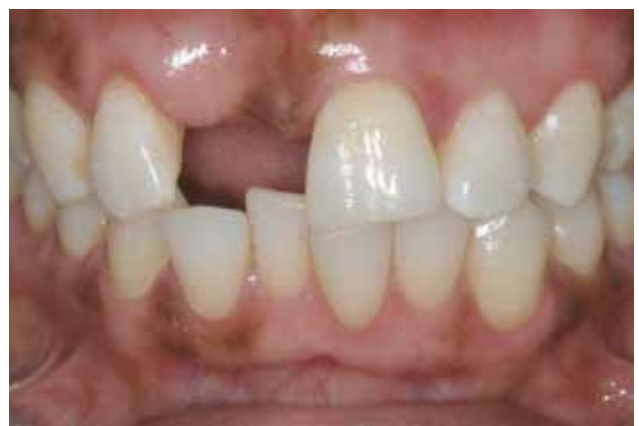
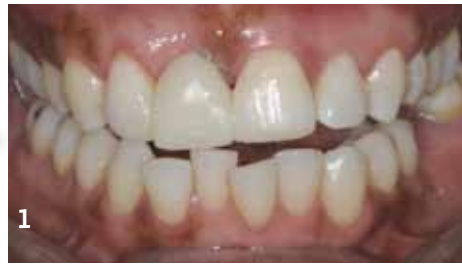
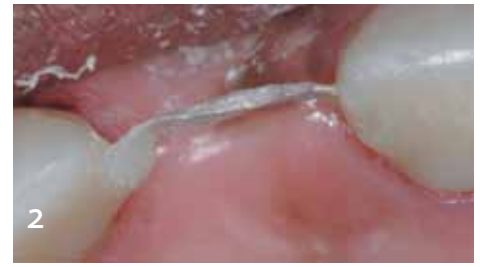Figure 3: Pre-treatment, retracted view.

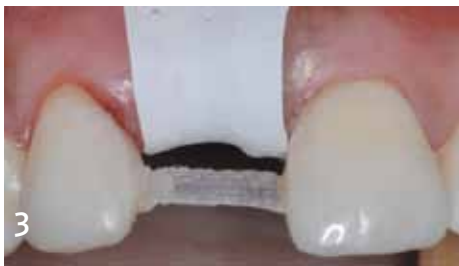Technique Steps



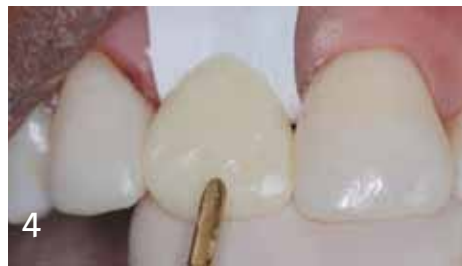1 After the mock-up.



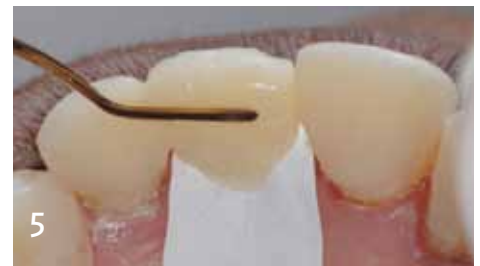2 Ribbon cemented in place with Insure resin cement (Cosmedent) and overlaid with Renamel Nano (Cosmedent).



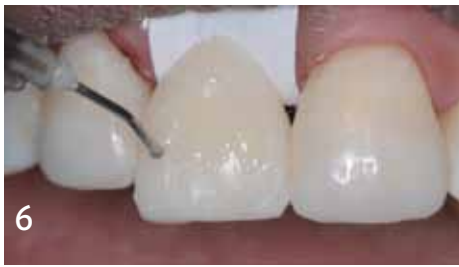3 Teflon tape was placed over the gingival tissue to aid in the creation of a smooth gingival surface for the pontic.



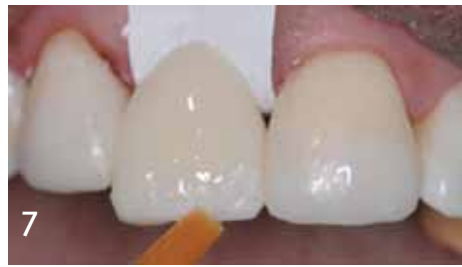4 Application of nano-fill composite over the Ribbon to form the dentin layer of the tooth surface.



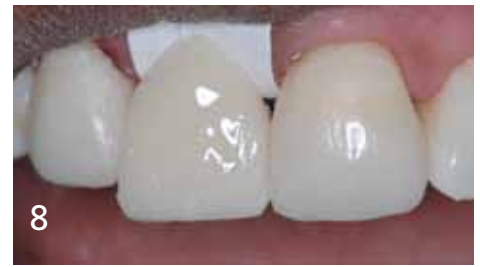5 Application and sculpting of lingual surface with nano-fill.



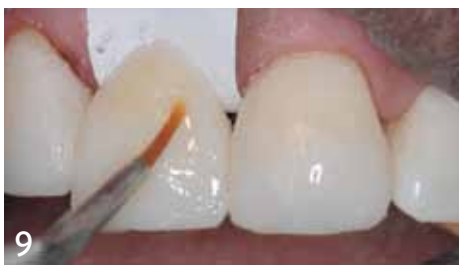6 Addition of small amount of flowable Renamel Microfill.



7 Smoothing flowable Renamel Microfill with Cosmedent #3 brush.



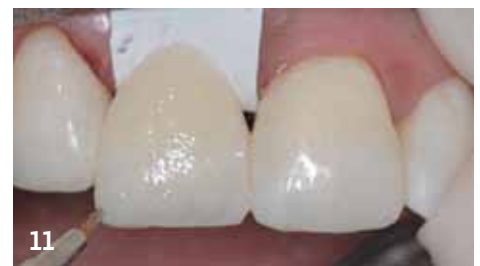8 Polymerized flowable creating the artist's canvas.



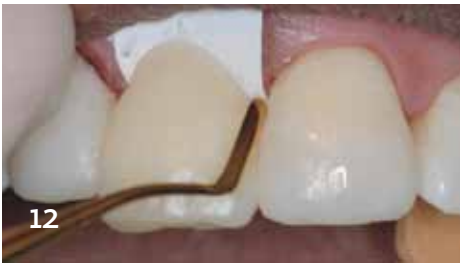9 Creation of cervical chroma.



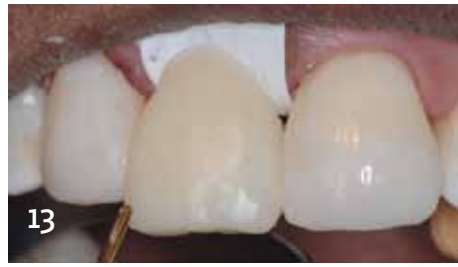10 Gray tint applied to enhance incisal translucency.



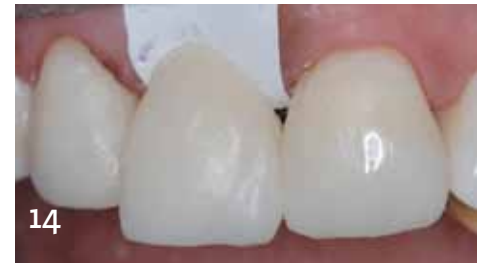11 Gray tint was added to the incisal third.



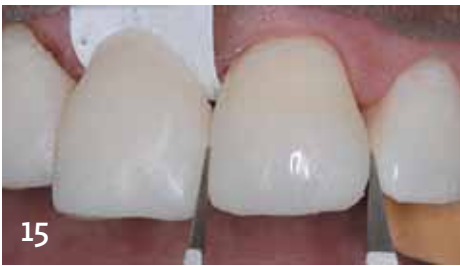To create the enamel surface, Renamel Microfill was placed and sculpted to the exact proximal contour while at the same time slightly over-contouring from the facial.



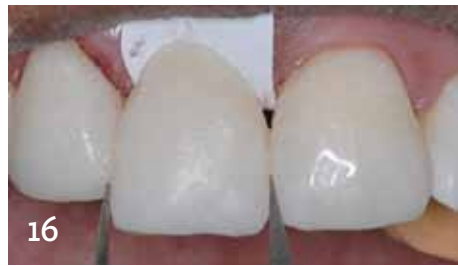Great attention was given to the proper formation of line angles and embrasures.



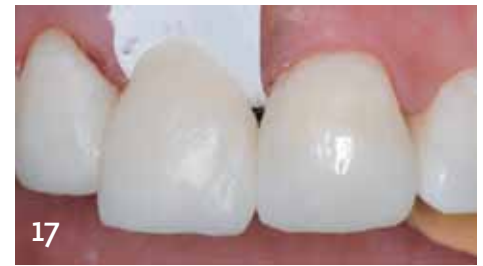This technique of sculpting greatly simplifies the final technique of contouring, finishing, and polishing.



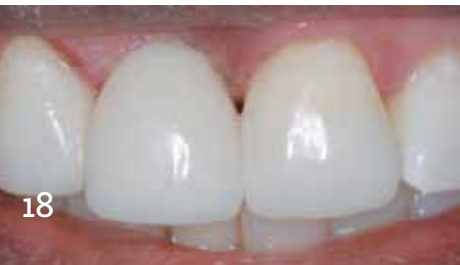Prior to finishing, measurements were taken from the mesial of the lateral incisor to lateral incisor with a digital boley gauge and then divided by two, to determine the total width of space needed for both central incisors.



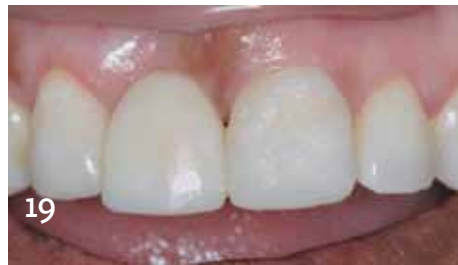Symmetry is accomplished in the "eyes" of the dentist. Angulation and inclination have to be done by "eye-balling" it.



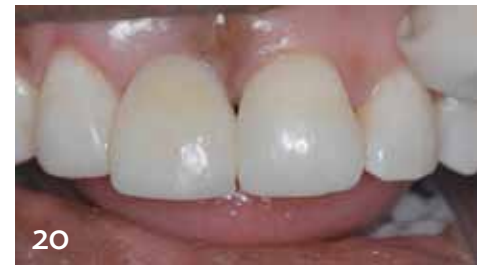Completed restoration prior to polishing.



Polishing completed; notice lack of gingival chroma.



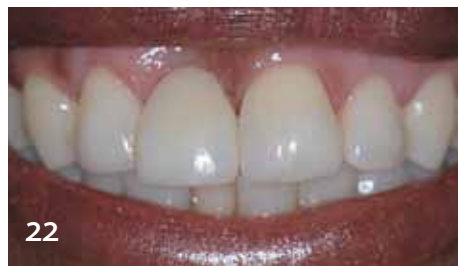Notice moist cotton pellet on adjacent central to prevent dessication to achieve perfect color match.



More gingival tint was added to the cervical third prior to final microfill; notice the increased chroma.



What a difference a new smile can make!



Finished case, immediately postoperative.



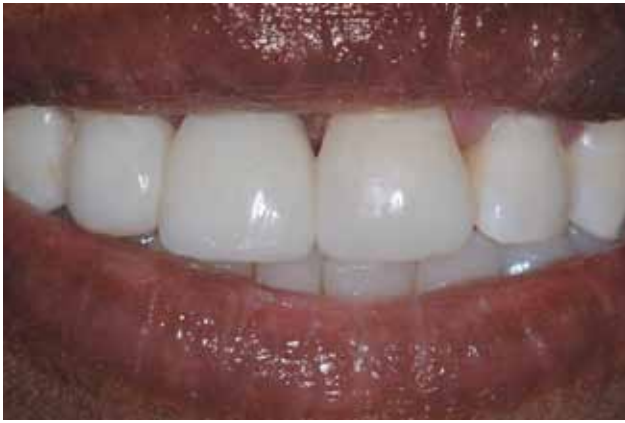


Figure 4: Postoperative evaluation confirmed that the gingival chroma needed to be enhanced.

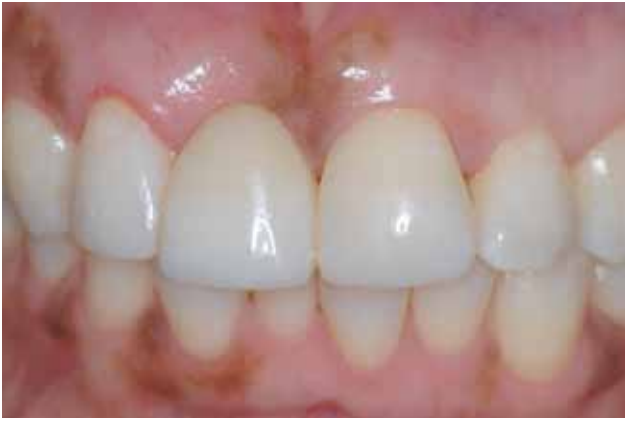

Figure 5: One year after treatment.



Figure 6: One year after treatment—a very happy patient!

I placed a thin moist cotton pellet on the adjacent tooth to keep it from desiccating, a great trick to help determine correct tooth color. Because the cotton pellet keeps the tooth moist it is easier to see the perfect color throughout the procedure. I added a little more tint to the gingival surface of the pontic in an attempt to create a perfect match.

Finishing was completed with the Brasseler ET contouring system and polishing was completed with Flex-discs, Flexi-points, Flexi-cups, Flexi-strips, Enamelize polishing paste and Felt Flexi-buffs.

Rewards

Immediately after treatment Diane said, "I now have a beautiful smile—it has lifted my self-esteem." One year later, Diane's self-esteem is at its highest. She says, "It feels good when you can smile and know that the world is smiling with you (Fig 5). I smile all the time now, but for 10 years I couldn't. Whenever I looked in the mirror I saw a monster; today, I see a beautiful woman. The GBAS program and Dr. Mopper gave me my life back!"

Diane also recounts the difference having her smile back has made in her life. She now can go out in the world with her head held high, and she can look people in the eye without being embarrassed. Her new smile has had such an impact on her that she now wants to be a spokesperson against domestic violence.

Diane's newfound confidence and zest for life reaffirmed for me how much patients really do appreciate our work; a smile truly is contagious.

What a difference a smile can make. Now Diane smiles not just with her lips and teeth, she smiles with her whole face (Fig 6)!

Volunteering for the Give Back a Smile program was incredibly rewarding for my staff and me. Restoring Diane's smile reminded us of the significance of a smile in a person's life. If you are not currently volunteering with GBAS, I strongly encourage you to do so.

Acknowledgment

The author thanks his partner, Dr. Dennis Hartlieb, for his assistance with this case.

References

1. Radz G. Beyond the Maryland bridge. *J Cosmetic Dent.* 1996;12(1):18-22.
2. Benjamin G, Kurtzman GM. An indirect matrix technique for fabrication of fiber-reinforced direct bonded anterior bridges. *Compend Contin Educ Dent.* 2010;31(1):60-4.
3. Piovesan EM, Demarco FF, Piva E. Fiber-reinforced fixed partial dentures: a preliminary retrospective clinical study. *J Appl Oral Sci.* 2006;14(2):100-4. **JCD**



Dr. Mopper is in private practice in Glenview, Illinois, and teaches CE in bonding at the University of Iowa and the University of Illinois. He is an Accredited Fellow member of the AACD and is the recipient of two awards from the AACD: Award of Excellence in Cosmetic Dental Education and Outstanding Contribution to the Art & Science of Cosmetic Dentistry. Disclosure: The author is co-owner of Cosmedent, Inc.